



# Correction of ischemic optic neuropathy in rats by carbamylated darbepoetin

Anna A. Peresyphkina<sup>1</sup>

<sup>1</sup> Belgorod State National Research University, 85 Pobedy St., Belgorod, 308015 Russia

Corresponding author: Anna A. Peresyphkina ([peresyphkina\\_a@bsu.edu.ru](mailto:peresyphkina_a@bsu.edu.ru))

Academic editor: Oleg Gudyrev ♦ Received 29 December 2017 ♦ Accepted 19 March 2018 ♦ Published 28 March 2018

Citation: Peresyphkina AA (2018) Correction of ischemic optic neuropathy in rats by carbamylated darbepoetin. Research Result: Pharmacology and Clinical Pharmacology 4(1): 43–50. <https://doi.org/10.3897/rrpharmacology.4.25262>

## Abstract

**Introduction:** The protective effects of carbamylated darbepoetin on the model of ischemic optic neuropathy in rats were revealed.

**Objectives:** To increase the effectiveness of pharmacological correction of experimental ischemic optic neuropathy in an experiment by using carbamylated darbepoetin.

**Methods:** Measuring the microcirculation level in the retina of rats was carried out using laser Doppler flowmetry (LDF). Registration was done by the data acquisition system Biopac-systems MP-150 and AcqKnowledge 4.2 programme.

For microscopy and morphometry, the prepared microslides were scanned using Mirax Desk, a computerised archiving and image analysis system. Image analysis and morphometry were carried out by Panoramic Viewer 1.15.4.

**Results and discussion:** In the group with correction of ischemic optic neuropathy by carbamylated darbepoetin, 300 µg/kg, the microcirculation level increases by 41.9%,  $p < 0.05$  in comparison with the control group, but also below the norm values by 20.3%,  $p < 0.05$ . In the group with correction by recombinant erythropoietin, 50 IU/kg, the microcirculation rate increases by 36.7%,  $p < 0.05$  in comparison with the control group and significantly lower - by 23.3%,  $p < 0.05$  - in comparison with the group of intact animals. Qualitative and quantitative morphological indices (thickness of retinal layers) helped to reveal a neuroprotective effect of carbamylated darbepoetin to a greater extent than that of recombinant erythropoietin.

**Conclusion:** The obtained data allow drawing a conclusion about partial restoration of blood flow and preservation of neuronal retinal structures when correcting ischemic optic neuropathy in rats with carbamylated darbepoetin to a greater extent than with recombinant erythropoietin.

## Keywords

ischemic optic neuropathy, rats, carbamylated darbepoetin, morphometry, retinal microcirculation

## Introduction

Ischemic optic neuropathy usually has a sudden onset, in some cases there is a progressive visual loss within 2 weeks (Riordan-Eva 2004). The clinical signs of op-

tic neuropathy are acute or chronic vision loss with a visual field defect, dyschromatopsia and a relative afferent pupillary defect (Prasad et al. 2010, Behbehani 2007, Hornyak et al. 2009). In order to make a correct diagnosis, it is necessary to examine the eye fundus (Rizzo et al.

2002) and to undertake electrophysiological (Holder et al. 2009), serological and genetic tests (Purvin 2000).

Non-arteritic anterior ischemic optic neuropathy is the most common form of ischemic optic neuropathy. Patients are usually over 50 years with vasculopathogenic risk factors (diabetes, arterial hypertension etc.) (Berry et al. 2017).

Atrophy of the inner layers of the retina is observed in the eyes with non-arteritic ischemic optic neuropathy (Rebolleda et al. 2015), but a significant part of the layer of nerve fibres and the layer of ganglion cells is preserved in patients even with no light perception (Miki et al. 2015).

The morphological changes include severe oedema after the onset of non-arteritic ischemic optic neuropathy, which rapidly turns into atrophy. Within 2 months, in more than 80% of patients, the thickness of the nerve fibres' layer is below the normal range (Kernstock et al. 2014).

In the treatment of retinal and optic nerve ischemia, they use drugs that improve retinal microcirculation and rheological blood properties (rheopolyglukin, pentoxifylline), vasodilators (eufyllin, xanthinol nicotinate etc.) (Moshetova et al. 2009).

At present, there is no unique and well-proven method of treating non-arteritic anterior ischemic optic neuropathy, despite the fact that it is the main pathology that affects the optic nerve in elderly people (Nuzzi and Monteu 2017).

Modified erythropoietin has been created – carbamylated erythropoietin – which has no erythropoietic effect, but at the same time keeps its neuroprotective properties.

Darbepoetin is a hyperglycosylated variant of recombinant human erythropoietin and, when compared to natural erythropoietin, darbepoetin has a three-fold longer half-life. For darbepoetin, it has been proved that it is as an equally effective neuroprotective agent as erythropoietin (Kertmen et al. 2014). At the same time, in animal models, its effectiveness in case of strokes was the same when administered weekly in comparison to the daily use of erythropoietin (Grasso et al. 2009). Thus, its effective dose is less and its application is less frequent than that of erythropoietin.

The assumption is that carbamylated darbepoetin will exhibit a protective effect on the model of ischemic optic neuropathy. The advantage of carbamylated darbepoetin against darbepoetin is that there is no influence on erythropoiesis.

In view of the above, the study relevance can be seen in studying the protective effects of carbamylated darbepoetin along with evaluating morphometric and microcirculatory changes in the retina in rats when ischemic optic neuropathy is corrected.

## Objectives

To increase the effectiveness of pharmacological correction of ischemic optic neuropathy in an experiment using carbamylated darbepoetin.

## Methods

The experiments were made on Wistar male rats weighing 225-275 g. For the study, the rats had no external signs of disease and had passed through quarantine. The ethical principles for handling laboratory animals were followed in compliance with “The European Convention for the Protection of Vertebral Animals Used for Experimental and Other Scientific Purposes. CETS No. 123”. All operations and other manipulations in rats were carried out under general anaesthesia with intraperitoneal (i/p) administration of an aqueous solution of chloral hydrate in a dose 300 mg/kg of rat mass.

The following experimental groups were included in the study: the first group (n = 10) – a group of intact animals, the second group (n = 10) – a group with simulating ischemic optic neuropathy (control), the third group (n = 10) – included animals with correction of ischemic optic neuropathy by carbamylated darbepoetin (Carbamylated darbepoetin, injectable solution, Pharmapark Ltd, Russia); the fourth group (n = 10) – included animals with the correction of pathology by recombinant erythropoietin (“Epokrin” epoetin alfa, Federal State Unitary Enterprise “State Research Institute of Highly Pure preparations”, Russia) (reference drug).

Based on the literature data, recombinant erythropoietin in a dose 50 IU/kg of rat mass has no effect on erythropoiesis, but has a retinoprotective effect (Shabelnikova 2016).

Simulation of the ischemic optic neuropathy was performed by daily i/p injection of a non-selective inhibitor of NO-synthases N-nitro-L-arginine methyl ester (L-NAME) (Sigma, Germany) in rats in a dose of 12.5 mg/kg in the form of an aqueous solution for 28 days and a single increase in intraocular pressure (IOP) to 110 mmHg by applying mechanical pressure to the anterior chamber of the eye (Shabelnikova 2016) for 5 minutes on the 26<sup>th</sup> day of the experiment.

Carbamylated darbepoetin was injected subcutaneously (s/c) in a dose of 300 µg/kg of rat mass to the withers area once every 3 days (1<sup>st</sup>, 4<sup>th</sup>, 7<sup>th</sup>, 10<sup>th</sup>, 13<sup>th</sup>, 16<sup>th</sup>, 19<sup>th</sup>, 22<sup>nd</sup>, 25<sup>th</sup> and 28<sup>th</sup> days of the experiment), 30 minutes before administering L-NAME.

In the fourth group of animals, recombinant erythropoietin was injected into the withers area in a dose of 50 IU/kg of rat mass (Peresyphkina et al. 2014) once every 3 days, 30 minutes before administering L-NAME.

To measure blood pressure in rats (in the tail) on the 29<sup>th</sup> day of the experiment, a non-invasive blood pressure measurement system was used in small animals NIBP200 within the data acquisition system Biopac-systems MP-150 (USA).

The measurement of the microcirculation level in the rats' retina was done by using the LDF method on the 29<sup>th</sup> day of the experiment under general anaesthesia. Registration was done with the help of the data acquisition system Biopac-systems MP-150 and the TSD-144 needle probe (USA) using the AcqKnowledge 4.2 programme. After anaesthetising the animal, the microcirculation lev-

el was assessed at ten points around the eyeball with the duration of recording the microcirculation level readings at one point being 20 seconds. Based on the results of the microcirculation level at each point, the mean was calculated, which was considered as an indicator of the retinal microcirculation level in a given experimental animal. The microcirculation value in the animals' group was calculated as the mean of the values obtained for each experimental animal in the group (Peresytkina et al. 2016).

After measuring the blood flow in the retina, the eyes were completely removed along with the adjacent structures on the 29<sup>th</sup> day of the experiment for morphometric examination and were fixed by immersion in 10% formalin solution. After fixing, the eyes were sectioned into two parts through the centre and both halves were processed into paraffin by routine methods. Also in the meridian direction, serial sections were made with a thickness of 5-7  $\mu\text{m}$ , which were stained with haematoxylin and eosin. The stages of histological processing were performed using Leica equipment (Germany). For microscopy, morphometry and archiving, the prepared microslides were scanned using Mirax Desk, a computerised archiving and image analysis system. Image analysis and morphometry were carried out by a Panoramic Viewer 1.15.4. The thickness of the layers of the retina was measured in a strictly perpendicular direction to within one hundredth of a micrometre. In each animal, five representative areas, free from artifacts of treated material, were measured. The quantitative data were recorded in MS Excel spreadsheets.

For all the data, descriptive statistics were applied and the data were checked for the distribution normality. The type of distribution was determined by the Shapiro-Wilk criterion. At a normal distribution, the mean value (M) and the standard error of the mean (m) were calculated. At an abnormal distribution, the median (Me) and the quartile range (QR) were calculated. The intergroup differences were analysed by parametric (Student's t-test) or non-parametric (Mann-Whitney test) methods, depending on the distribution type. The differences were determined at a 0.05 significance level. The statistical analysis was performed using the software Statistica 10.0.

## Results and discussion

The authors used on Wistar rats a model of ischemic optic neuropathy, pathogenesis of which, in particular, is associated with the development of arterial hypertension affected by daily i/p administration of L-NAME in a dose 12.5 mg/kg/day for 28 days (Belous et al. 2015) (SBP  $139.2 \pm 5.4$  mmHg, DBP  $104.2 \pm 4.7$  mmHg in the group of intact animals; SBP  $204.8 \pm 10.0$  \* mmHg, DBP  $164.2 \pm 5.9$  \* mmHg in the group with pathology simulation, \* -  $p < 0.05$  in comparison with the group of intact animals).

To confirm the formation of the ischemic optic neuropathy in rats on the 29<sup>th</sup> day of the experiment, the results of LDF in the retina and of morphometric studies were used.

The results of measuring the microcirculation level in the retina in the experimental animals are shown in Table 1.

**Table 1.** Results of LDF in the Retina in Experimental Animals on 29th Day of the Experiment (M  $\pm$  m; n = 10).

Experimental groups	Microcirculation level, PU
Intact	743.0 $\pm$ 20.9
Control	417.2 $\pm$ 13.1*
Correction by carbamylated darbepoetin, 300 $\mu\text{g}/\text{kg}$	592.4 $\pm$ 9.6* <sup>y</sup>
Correction by recombinant erythropoietin, 50 IU/kg	570.5 $\pm$ 10.5* <sup>y</sup>

Note: \* -  $p < 0.05$  compared with the group of intact animals, y -  $p < 0.05$  compared with the control group, PU - perfusion units.

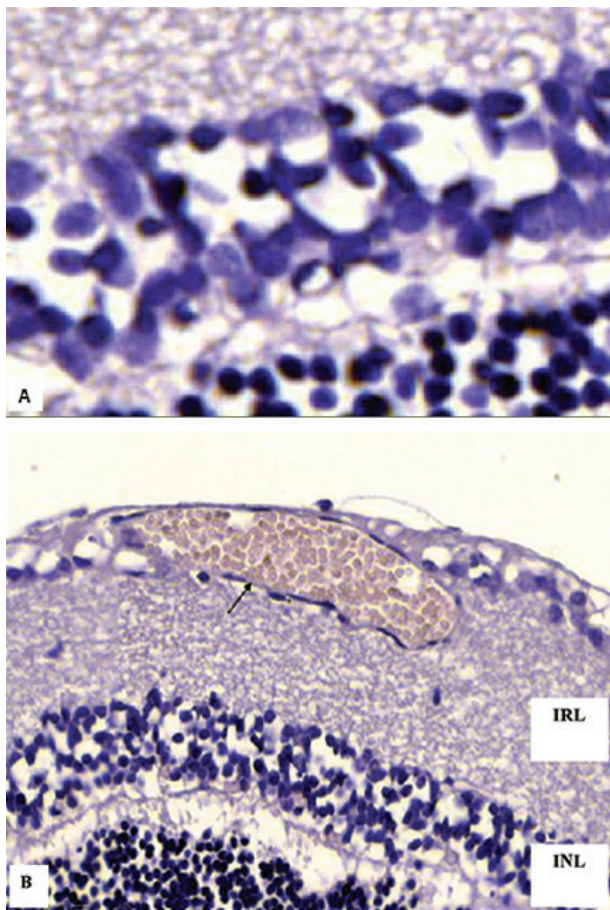
In the group with simulated ischemic optic neuropathy, the microcirculation level significantly decreases by 43.9%,  $p < 0.05$  in comparison with the group of intact animals. In the group with the correction of pathology by carbamylated darbepoetin, this indicator significantly increases by 41.9%,  $p < 0.05$  in comparison with the group without correction, but it is also 20.3% lower than the norm values,  $p < 0.05$ . In the group with correction by recombinant erythropoietin, the microcirculation level in the retina significantly increases by 36.7%,  $p < 0.05$  in comparison with the group without correction and is significantly lower - by 23.3%,  $p < 0.05$  - in comparison with the group of intact animals. By the degree of microcirculation correction in the retina, the drugs under study do not differ significantly from one another, 3.9%,  $p = 0.09$ .

The data obtained from measuring the microcirculation level allow one to speak of a partial restoration of blood flow in the retina when correcting the experimental ischemic optic neuropathy with the test drugs.

In the group of animals with simulating experimental pathology, all rats showed pronounced morphological changes in the neuronal structures of the retina affected by circulatory disturbances. In the layer of rods and cones, represented by the dendrites of photoreceptor neurons, discomplexation of the structure was revealed. The layer lost its normal radial striation, created due to the compact arrangement of neuronal processes and obtained a spongiform loose shape (Figs. 1 and 2).

Signs of dendrites' destruction through lumpy decomposition are common in the form of their transformation into oxyphilic chaotically located globular structures.



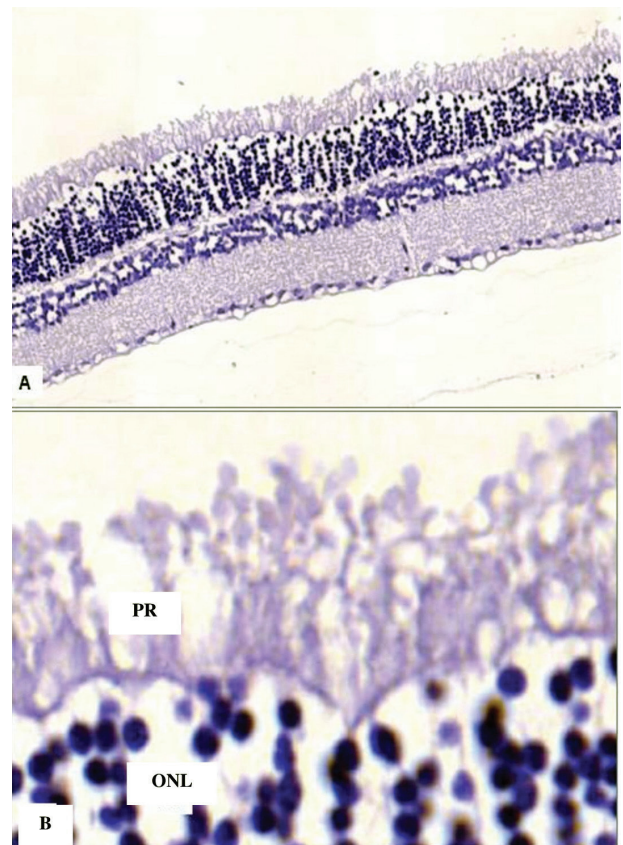


**Figure 1.** Retinal changes in experimental ischemic optic neuropathy: (A) discomplexation of dendrites in the photoreceptor layer and perikaryons in the outer nuclear layer to form intercellular clefts of oedematous type (B) discomplexation of structures and oedematous loose shape of inner nuclear (INL) and inner retinal (IRL) layers, pronouncedly full-blooded small vein on the border of the inner retinal and ganglionic layers. Stained with haematoxylin and eosin. x200.

Similar changes in the outer and inner nuclear layers were observed in the form of decompaction of the nucleus arrangement and formation of spongiform clefts, probably due to both intercellular oedema and the lytic changes in the perikaryons of photoreceptor neurons (Fig. 2).

The retinal layers were subjected to spongiform transformation. Within the area of the optic nerve disc, an obvious thinning of the retinal layers is microscopically revealed. The most severe changes were observed at the edges of the optic nerve disc (Fig. 3) and in the ganglionic layer of both the posterior and anterior parts of the retina.

The edges of the optic disc are sharply oedematous, with pronounced cell devastation. In the ganglionic layer, there is a full-blown peri- and intracellular oedema and a part of neurons with lytic changes in pericaryons. All these changes are accompanied by severe circulatory disturbances, mainly in the small veins and venous part of the microcirculatory bed in the form of extensive plethora, erythrosta-

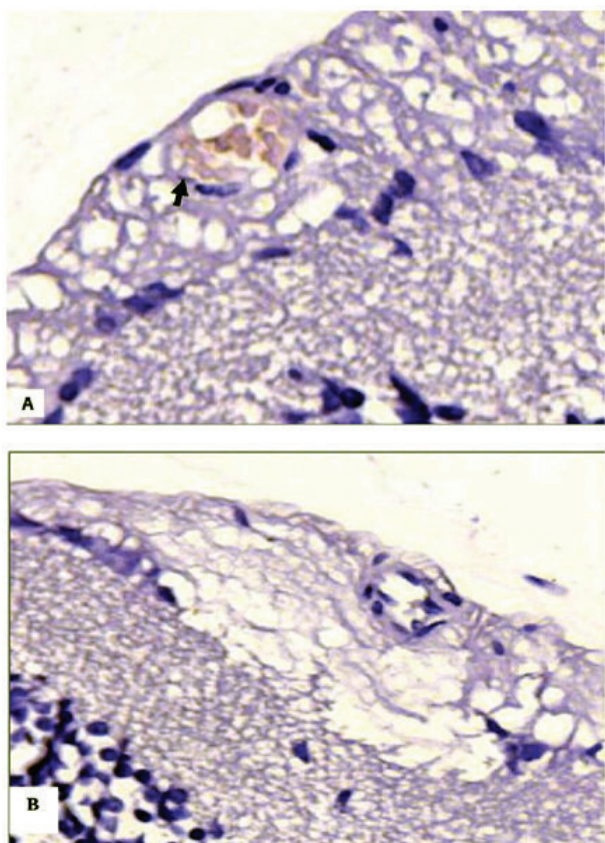


**Figure 2.** Retinal changes in experimental ischemic optic neuropathy: marked discomplexation of the structure of the photoreceptor (PR) and outer nuclear (ONL) layers; in the photoreceptor layer changes of dendrites of rods and cones through lumpy decomposition. Stained with haematoxylin and eosin. x400.

sis and sludges in venules (Figs. 1 and 3); in the centres of pronounced venous plethora, the inner glial boundary membrane is often destroyed and intraocular haemorrhages in the posterior chamber are detected (Fig. 4).

In the group of animals with administered carbamylated darbepoetin, significant differences in the retinal structure were revealed in comparison with those developing in experimental pathology. The overall structure of the neuronal layers of the retina is almost unchanged. The discomplexation of structures and oedematous changes, similar to those in ischemic optic neuropathy, are moderately expressed. The main changes are observed in the photoreceptor and ganglionic layer (Fig. 5). The optic nerve disc and the nerve itself have no signs of damage. At the same time, circulatory disorders in both the retina and extraocular vessels remain mainly in the form of venous plethora and stasis in the vessels of the microcirculatory bed.

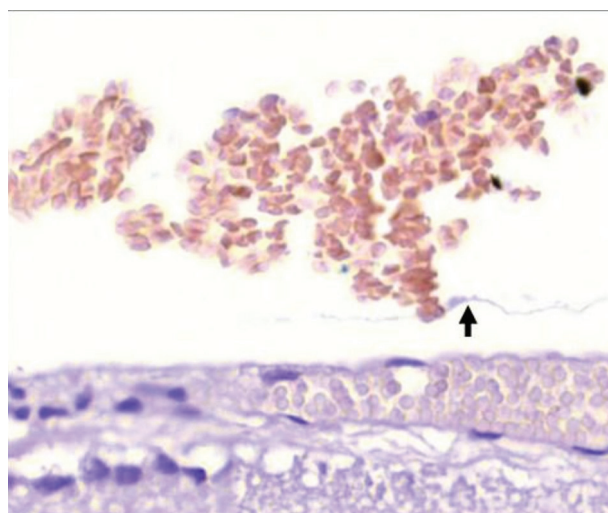
In the group with the recombinant erythropoietin correction, the structure of the retinal layers is unchanged; there are observed hypertensive changes of the orbital artery, uneven contours of the intima with deformation of the endothelium. Despite significant circulatory disorders in the microcirculatory vessels of the retina, as well



**Figure 3.** Details of changes in the optic nerve disc in experimental ischemic optic neuropathy: (A) discomplexation of structures in the inner retinal layer (bottom part of the microphoto), pronounced pericellular oedema, lytic changes of individual neurons, plethora and erythrostasis in the venule (arrow) in the ganglionic layer. (B) pronounced oedema at the edge of the disc. Stained with haematoxylin and eosin. x200.

as extraocular vessels (Fig. 6), neuronal structures were relatively intact.

The most sensitive to the damaging effect in the used pathology model are the retinal layers formed by neuronal processes and synaptic contacts (photoreceptor and retinal layers). However, the preservation of the neuron body structures – their nuclei and perikaryons – can be evidence of their potential viability and capacity for restoring both neuronal processes, including the sensory



**Figure 4.** Changes in the retina in experimental ischemic optic neuropathy: a focus of pronounced venous plethora (bottom part of the microphoto) of the retina and intraocular haemorrhage; above the arrow is a fragment of a detached internal border glial membrane. Stained with haematoxylin and eosin. x200.

outer segments of rods and cones that make up the photoreceptor layer and the inter-neuronal connections.

The results of morphometry of retinal layers quantitatively confirm the described qualitative changes and together testify to the development of cellular destruction and atrophy of retinal layers in simulating ischemic optic neuropathy (Table 2).

A significant decrease was revealed in the thickness of the photoreceptor layer, which indicates damage to the perikaryons of photosensitive cells as well as to both segments (external and internal) of their dendrites in the control group. An increase in the thickness of the inner nuclear layer is mostly associated with oedematous changes. This can also explain an increase in the thickness of the inner retinal as well as ganglionic layers, although the spongiform changes in the retinal layer, similar to those in the white matter of the brain and spinal cord in case of blood circulation disorders, can reflect the destruction of both the neuronal processes and the synaptic contacts formed by them.

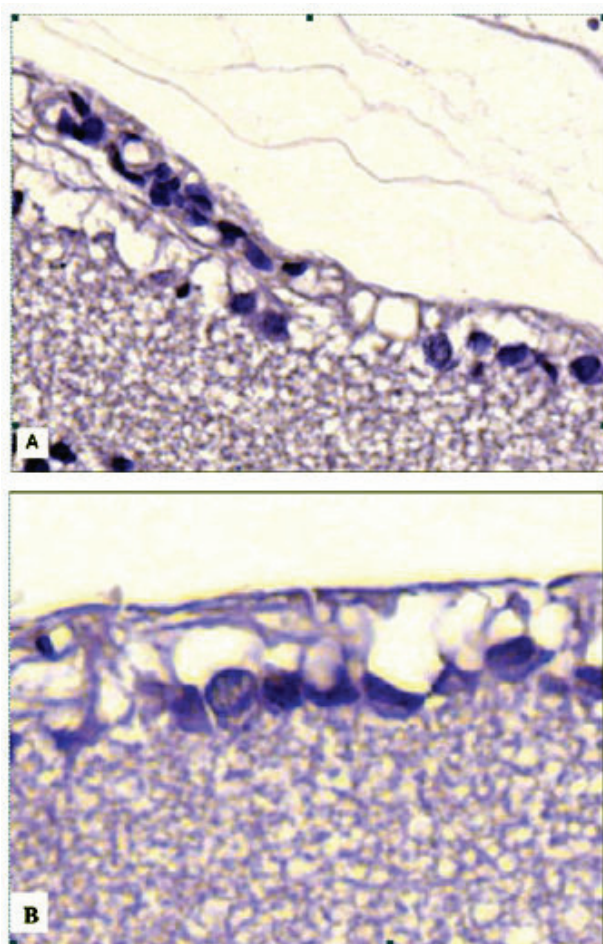
The neuroprotective effect of carbamylated darbepoetin is proved by morphometric indices of the thickness of the retinal layers (Table 2). In the ganglionic layer, even

**Table 2.** Thickness of Retinal Layers in Experimental Groups (M ± m).

Retinal layers	Experimental groups			
	Intact	Control	CD	RE
Photoreceptor layer	52.6 ± 1.7	13.9 ± 0.6*	52.6 ± 1.3	42.4 ± 1.5* <sup>y</sup>
Inner nuclear	26.4 ± 1.3	39.9 ± 0.6*	34.4 ± 0.6*	30.7 ± 1.5* <sup>y</sup>
Inner retinal	45.4 ± 2.6	53.7 ± 1.6*	46.0 ± 1.0 <sup>y</sup>	53.4 ± 2.1*
Ganglionic and nerve fibres	17.8 ± 1.0	22.3 ± 0.8*	18.2 ± 0.7 <sup>y</sup>	17.8 ± 1.0 <sup>y</sup>

Note: \* – p<0.05 compared with the group of intact animals, y – p<0.05 compared with the control group. CD – group with correction by carbamylated darbepoetin, 300 µg/kg, RE – group with recombinant erythropoietin correction, 50 IU/kg.



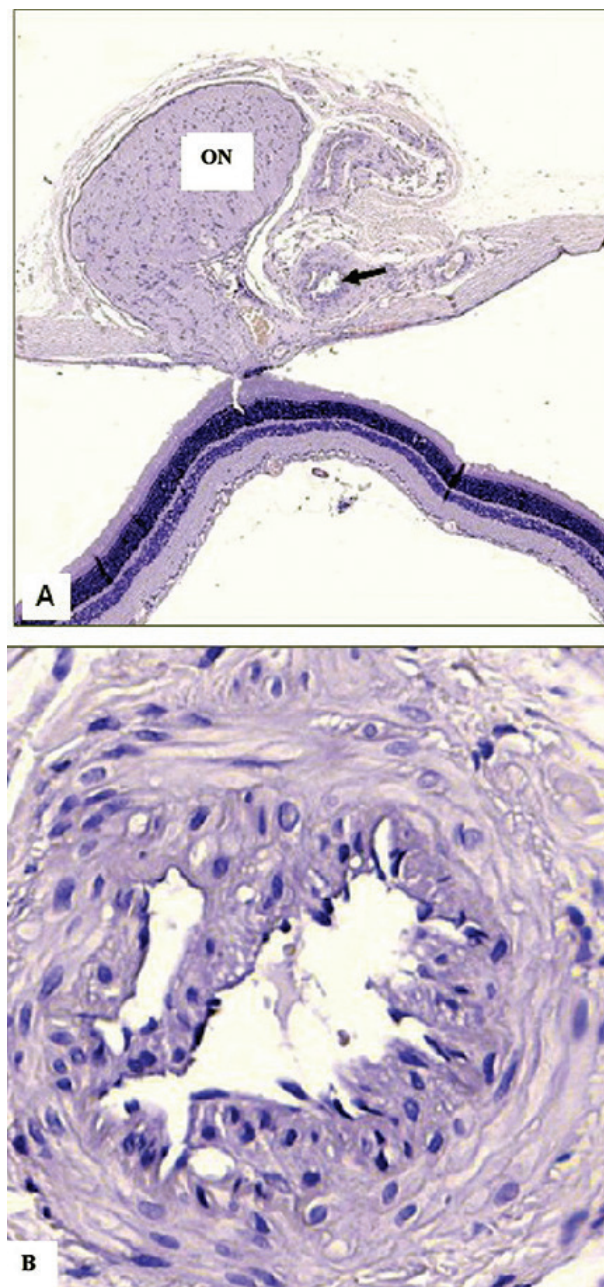


**Figure 5.** Details of retinal changes in the group with correction by carbamylated darbepoetin: spongiosis of the inner retinal layer (bottom parts of the microphotos), perineuronal oedema in the ganglionic layer (top parts). Stained with haematoxylin and eosin. x400.

with pronounced perineuronal oedema and chromatolysis, the general structure of the neurons and their nuclei were preserved, which may evidence their viability.

By the quantitative parameters of the retinal layer thickness, the neuroprotective effect is somewhat less expressed in recombinant erythropoietin than in carbamylated darbepoetin.

Thus, by qualitative and quantitative morphological indices, the neuroprotective effect of carbamylated darbepoetin in a dose of 300  $\mu\text{g}/\text{kg}$  was revealed on the model of ischemic optic neuropathy in Wistar rats. Administration of the drug did not affect the morphological changes in the blood vessels, but the neuronal structures of the retina remained more intact than in the pathology simulating group. A similar pattern was found in the group with administration of recombinant erythropoietin in a dose of 50 IU/kg. Despite significant circulatory disturbances in the microcirculatory vessels of the retina, as well as in extraocular vessels, the neurons were relatively intact.



**Figure 6.** Details of retinal changes in the group with correction by recombinant erythropoietin: (A) posterior pole of the eye with optic nerve (ON) and posterior retina. The structure of the retinal layers is unchanged; the intraorbital artery is shown by arrow. (B) hypertensive changes in the orbital artery (details from Fig. A): uneven intima contours with deformation of the endothelium in the form of “palisade”, dystrophic changes in smooth medial myocytes, destruction of the internal elastic membrane. Stained with haematoxylin and eosin. x200.

The main factors in the development of retinal angiopathy are disorders of general haemodynamics and local changes in the vessel walls. Amongst the local changes, the most important are damage to the vascular endothelium (Tinjust et al. 2002).

In this connection, it is necessary to find new methods of retinoprotection to possibly reduce the negative consequences of ischemia of the retina and the optic nerve. The segment of medicines to treat neurovascular diseases of the retina as a complication of arterial hypertension is to be expanded due to an increase in the disease rate and lack of remedies for specific correction of ischemic damage to the retinal vasculature.

## Conclusion

In the group with correcting ischemic optic neuropathy by carbamylated darbepoetin in a dose of 300 µg/kg with subcutaneous administration every 3 days (1<sup>st</sup>, 4<sup>th</sup>, 7<sup>th</sup>, 10<sup>th</sup>, 13<sup>th</sup>, 16<sup>th</sup>, 19<sup>th</sup>, 22<sup>nd</sup>, 25<sup>th</sup>, 28<sup>th</sup> days of the experiment), the microcirculation level is significantly increased by 41.9%,  $p < 0.05$  compared with the control group, but is also 20.3% lower than the normal values,  $p < 0.05$ . In the group with the correction by recombinant erythropoietin in a dose of 50 IU/kg, the microcirculation level in the

retina significantly increases by 36.7%,  $p < 0.05$  in comparison with the control group and is significantly lower (23.3%),  $p < 0.05$  in comparison with the group of intact animals. By the degree of microcirculation correction in the retina, the test drugs do not differ from each other significantly, 3.9%,  $p = 0.09$ . The data obtained make it possible to suggest partial restoration of the blood flow in the retina when correcting experimental ischemic optic neuropathy by the drugs under study.

According to the qualitative and quantitative morphological indices, a neuroprotective effect of carbamylated darbepoetin in a dose of 300 µg/kg was revealed on a model of ischemic optic neuropathy in Wistar rats. Administration of the drug did not affect the morphological changes in the blood vessels, but the neuronal structures of the retina remained more intact than in the pathology simulating group. A similar pattern was found in the group using recombinant erythropoietin in a dose of 50 IU/kg. Despite significant circulatory disturbances in the microcirculatory vasculature of the retina, as well as in extraocular vessels, the neurons were relatively intact.

## References

- Behbehani R (2007) Clinical Approach to Optic Neuropathies. *Clin Ophthalmol* 3: 233–246. [Full text]
- Belous AS, Lavrinenko KI, Kudina IV et al. (2015) Evaluation of Endothelioprotective Properties of Ultra-small Doses of Antibodies to VEGF on the 28-day Model of Endothelial Dysfunction. Conference proceedings Prospects for the Development of Science and Education, in 13 volumes. Tambov: LLC “Consulting company Yukom” (RU), 42–44. [in Russian]
- Berry S, Lin WV, Sadaka A, Lee AG (2017) Nonarteritic Anterior Ischemic Optic Neuropathy: Cause, Effect, and Management. *Eye Brain* 9: 23–28. <https://doi.org/10.2147/EB.S125311> [PubMed] [PMC]
- Grasso G, Graziano F, Sfacteria A et al. (2009) Neuroprotective Effect of Erythropoietin and Darbepoetin Alfa After Experimental Intracerebral Hemorrhage. *Neurosurgery* 65(4): 763–769; discussion 769–770. <https://doi.org/10.1227/01.NEU.0000347475.73347.5F> [PubMed]
- Holder GE, Gale RP, Acheson JF, Robson AG (2009) Electrodiagnostic Assessment in Optic Nerve Disease. *Curr Opin Neurol* 22: 3–10. <https://doi.org/10.1097/WCO.0b013e328320264c> [PubMed]
- Hornyak M, Digre K, Couldwell WT (2009) Neuro-ophthalmologic Manifestations of Benign Anterior Skull Base Lesions. *Postgrad Med* 121: 103–114. <https://doi.org/10.3810/pgm.2009.07.2036> [PubMed]
- Kernstock C, Beisse F, Wiethoff S et al. (2014) Assessment of Functional and Morphometric Endpoints in Patients with Non-arteritic Anterior Ischemic Optic Neuropathy (NAION). *Graefes Arch Clin Exp Ophthalmol* 252(3): 515–21. <https://doi.org/10.1007/s00417-014-2572-z> [PubMed]
- Kertmen H, Güler B, Yilmaz ER et al. (2014) The Comparative Effects of Recombinant Human Erythropoietin and Darbepoetin-alfa on Cerebral Vasospasm Following Experimental Subarachnoid Hemorrhage in the Rabbit. *Acta Neurochir* 156(5): 951–962. <https://doi.org/10.1007/s00701-014-2008-x> [PubMed]
- Miki A, Endo T, Morimoto T et al. (2015) Retinal Nerve Fiber Layer and Ganglion Cell Complex Thicknesses Measured with Spectral-domain Optical Coherence Tomography in Eyes with No Light Perception Due to Nonglaucomatous Optic Neuropathy. *Jpn J Ophthalmol* 59(4): 230–235. <https://doi.org/10.1007/s10384-015-0386-0> [PubMed]
- Moshetova LK, Nesterov AP, Egorov EA (2009) Ophthalmology. Clinical Recommendations. 2nd ed., corr. and add. Moscow: GEOTAR-Media, 352 p. [in Russian]
- Nuzzi R, Monteu F (2017) Use of Intravitreal Dexamethasone in a Case of Anterior Ischemic Optic Neuropathy. *Case Rep Ophthalmol* 8(2): 452–458. <https://doi.org/10.1159/000479785> [PubMed] [PMC]
- Peresyapkina AA, Pokrovskiy MV, Shabelnikova AS et al. (2014) Electrophysiological and Histomorphometric Changes in the Rat Retina in Pharmacological Preconditioning with Erythropoietin, Nicorandil in Model of Ocular Ischemia-reperfusion. *Scientific statements BSU. Series: Medicine. Pharmacy* 1(182): 113–117.
- Peresyapkina AA, Gubareva VO, Levkova EA, Shabelnikova AS (2016) Correction of Retinal Angiopathy of Hypertensive Type by Minoxidil, Sildenafil in Experiment. *Research result: pharmacology and clinical pharmacology* 2(4): 34–44. <https://doi.org/10.18413/2500-235X-2016-2-4-34-44>
- Prasad S, Volpe NJ, Balcer LJ (2010) Approach to Optic Neuropathies: Clinical Update. *Neurologist* 16: 23–34. <https://doi.org/10.1097/NRL.0b013e328181be6fad> [PubMed]
- Purvin VA (2000) Optic Neuropathies for the Neurologist. *Semin Neurol* 20: 97–110. [PubMed]
- Rebolleda G, Sanchez-Sanchez C, Gonzalez-Lopez JJ et al. (2015) Papillomacular Bundle and Inner Retinal Thicknesses Correlate with Visual Acuity in Nonarteritic Anterior Ischemic Optic Neuropathy. *Invest Ophthalmol Vis Sci* 56: 682–92. <https://doi.org/10.1167/iovs.14-15314> [PubMed]

- Riordan-Eva P (2004) Clinical Assessment of Optic Nerve Disorders. *Eye* 18(11): 1161–1168. <https://doi.org/10.1038/sj.eye.6701575> [Full text]
- Rizzo JF 3rd, Andreoli C, Rabinov JD (2002) Use of Magnetic Resonance Imaging to Differentiate Optic Neuritis and Nonarteritic Ischemic Optic Neuropathy. *Ophthalmology* 109: 1679–1684. [PubMed]
- Shabelnikova AS (2016) Correction of Ischemic Damage to the Retina on Application of Pharmacological Preconditioning of Recombinant Erythropoietin. *Research result: pharmacology and clinical pharmacology* 2(2): 67–90. <https://doi.org/10.18413/2313-8971-2016-2-2-67-90>
- Tinjust D, Kergoat H, Lovasik JV (2002) Neuroretinal Function During Mild Systemic Hypoxia. *Aviat. Space Environ. Med* 73(12): 1189–1194. [PubMed]

## Contributors

- **Anna A. Peresytkina**, PhD in Biology, Associate Professor, Department of Pharmacology and Clinical Pharmacology, Institute of Medicine, Belgorod State National Research University. E-mail: [peresytkina\\_a@bsu.edu.ru](mailto:peresytkina_a@bsu.edu.ru). The author carried out experimental work, statistical processing and evaluation of retinoprotective activity in the experiment, as well as conducted analysis and interpreted the results.